

Macular holes: classification, epidemiology, natural history and treatment

Morten la Cour and Jakob Friis

Eye Department, Rigshospitalet, Copenhagen, Denmark

ABSTRACT.

Background: Macular hole is a retinal disease primarily affecting elderly women. Its overall prevalence in the Danish population is estimated to be 0.14%. The majority of cases are unilateral. The fully developed macular hole evolves through a series of stages starting with an impending hole. About half of impending macular holes regress spontaneously. The remaining half progress to full thickness macular holes. In a patient with a macular hole in one eye, the risk of development of a macular hole in the fellow eye is less than 2% if posterior vitreous detachment is present. If the posterior vitreous is attached, the risk is approximately 15%. If an impending hole is found in the other eye, the risk rises to 50%.

Treatment and outcomes: Macular hole surgery is able to close full thickness macular holes in approximately 90% of cases. Visual acuity of 20/50 or better can be obtained in approximately half of patients with recent onset of symptoms. Complications include retinal detachment, endophthalmitis, late reopening of an initially successfully closed hole and retinal pigment epithelial abnormalities. Retinal detachment should be expected in less than 5% of cases.

Key words: macular hole – epidemiology – natural history – pathogenesis – vitrectomy – macular hole surgery

Acta Ophthalmol. Scand. 2002; 80: 579–587

Copyright © Acta Ophthalmol Scand 2002. ISSN 1395-3907

Idiopathic macular hole is a rather common retinal disease affecting elderly people. Interest in the disease has increased dramatically since effective surgical treatment became available a decade ago (Kelly & Wendel 1991; Wendel et al. 1993).

Macular holes can be seen in highly myopic eyes, or following ocular trauma, but the great majority are idiopathic (Aaberg 1970). Biomicroscopically, a fully developed macular hole appears as a punched out, full thickness defect in the fovea (Fig. 1). Patients complain of metamorphopsia and loss of central vision.

Gass has described the evolution of the macular hole and defined the clinical ap-

pearance of the different stages of its development (Gass 1988, 1995). The earliest stage, according to Gass, is an impending hole, characterized by a yellow spot (stage 1a) or a yellow ring (stage 1b) in the fovea (Gass 1988, 1995). Stage 1 macular holes are difficult to diagnose biomicroscopically and even experienced observers disagree about the diagnosis in many cases (Gass & Joondeph 1990). Ocular coherence tomography (OCT) is helpful in diagnosing and characterizing macular holes and has revealed that a stage 1 hole appears as a cystic lesion in the inner retinal layers (Gass 1999; Gaudric et al. 1999; Azzolini et al. 2001; Haouchine et al. 2001). In stage 2 macu-

lar holes, there is a foveal full thickness defect less than 400 µm in diameter; these holes can be round, ovoid or slit-like in shape. The fully developed, stage 3 macular hole appears as a round, full thickness defect larger than 400 µm in diameter. Often the edge of the hole has a slightly serrated appearance, and fine striae may be seen radiating out on the retinal surface surrounding it (Fig. 1) (Kishi et al. 1995). In the majority of patients, a small vitreous opacity, or operculum, can be seen suspended in front of the lesion. In more chronic lesions yellow dots can be seen on the surface of the pigment epithelium at the bottom of the lesion (Hall-er 1999). Stage 4 macular holes appear similar to stage 3 holes except that in stage 4 holes there is complete posterior vitreous detachment, as frequently evidenced by a visible Weiss's ring. The characteristics of stage 1–4 macular holes are depicted in Table 1.

Most stage 1 and some stage 2 lesions are asymptomatic, especially if the other eye is normal (Ezra 2001). In later stages, patients complain of metamorphopsia and loss of central vision. The typical pin-cushion distortion metamorphopsias described by the majority of patients, and shown in Fig. 2 (Saito et al. 2000), is often helpful in the diagnosis of full thickness macular holes. Since its introduction, OCT has been recognized as an extremely useful tool for making or confirming diagnoses of macular hole, as well as for defining the stage of the lesion. Fluorescein angiography shows small, dotted areas of hyperfluorescence in the bottom of the hole in the majority of cases, and is sometimes helpful in differentiating macular hole from other conditions (Thompson

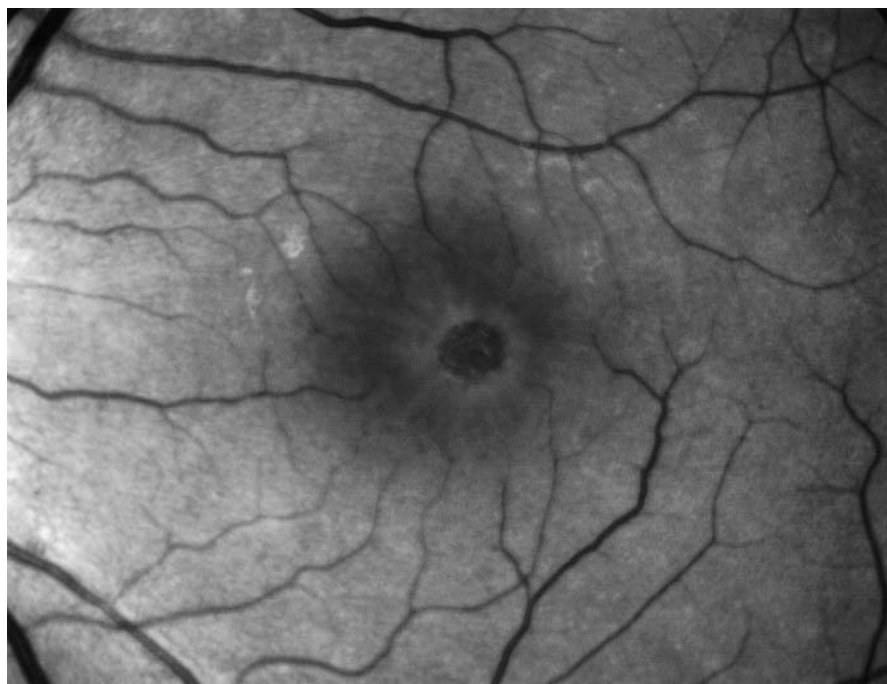


Fig. 1. Red-free fundus photograph of a stage 3 macular hole. Note the punched out appearance and the radiating striae in the vitreoretinal interface.

tiated from macular holes. In general, any diagnosis of a full thickness macular hole in an eye with visual acuity (VA) of 20/40 or better should arouse suspicion. If in doubt, OCT is often helpful.

Epidemiology of macular holes

Few population-based studies have reported on the prevalence of full thickness macular holes. The Beaver Dam Eye Study used fundus photography to evaluate fundus morphology in 4926 individuals over 42 years of age. It found full thickness macular holes to be prevalent in 0.3% of the population, with prevalence rates increasing from 0.0% in those between 43 and 54 years of age to 0.8% in people aged 75 years or more (Klein et al. 1994). If the prevalence found in the Beaver Dam Eye Study is normalized to the Danish population, an overall prevalence of 0.14% results. A follow-up to the Beaver Dam Eye Study found a 10-year incidence of macular holes in 0.7% of the population (Ronald Klein, personal communication). This corresponds to approximately 300 new cases per 1000000 citizens annually. The relatively frequent occurrence of macular holes was confirmed by the Blue Mountains Eye Study (Australia) and the Baltimore Eye Study (Rahmani et al. 1996; Mitchell et al. 1997). The majority of macular hole cases remain unilateral, and despite the high prevalence of the condition, it is not a common cause of blindness (Rahmani et al. 1996).

Macular holes affect women three times more often than men (Aaberg 1970; Eye Disease Case-Control Study Group

et al. 1994; Klein et al. 1995). The Watzke–Allen test has been widely used as a test in the diagnosis of macular hole. A positive Watzke–Allen test result represented an inclusion criterion in the Vitrectomy for Macular Hole Trial (Kim et al. 1995, 1996; Freeman et al. 1997). In this test a narrow slit beam is projected across the macular hole. The test is considered positive if the patient reports a gap in the slit. However, the introduction of OCT has made it apparent that the sensitivity of Watzke–Allen test in the diagnosis of full thickness macular holes is only around 60% (Tanner & Williamson 2000).

Full thickness macular holes must be differentiated from pseudoholes caused by epiretinal membranes (Martinez et al. 1994). This is important as epiretinal membranes are found in approximately two-thirds of eyes with macular holes (Klein et al. 1994; Cheng et al. 2000). Abortive macular holes may result in lamellar holes (Takahashi & Kishi 2000), in which only the inner part of the fovea is torn away from the retina. Lamellar holes may be difficult to distinguish from full thickness macular holes without OCT. In addition, atypical cases of cystoid macular oedema must sometimes be differen-

Table 1. Characteristics of stage 1–4 macular holes.

	Stage 1	Stage 2	Stage 3	Stage 4
Biomicroscopy	Yellow dot (stage 1a) or yellow ring (stage 1b)	Full thickness macular hole <400 μm in maximum diameter Round or oval Posterior vitreous attached	Full thickness macular hole >400 μm in maximum diameter Round Opculum may be seen Posterior vitreous attached	Full thickness macular hole >400 μm in maximum diameter Round Complete posterior vitreous detachment
Visual acuity	20/20–20/60	20/40–20/100	20/60–20/200	20/60–20/400
Symptoms	Asymptomatic or mild metamorphopsia	Metamorphopsia and loss of central vision	Loss of central vision and metamorphopsia	Loss of central vision and metamorphopsia
Prognosis	50% regress 40% progress to full thickness macular holes	15% close spontaneously 75% enlarge	< 5% close spontaneously 50% enlarge	<< 5% close spontaneously 20% enlarge
Candidacy for surgery	None	Excellent	Good	Possible

1994; Lewis et al. 1996; Kang et al. 2000). The Eye Disease Case-Control Study investigated risk factors for idiopathic macular holes in 198 cases and 1023 control subjects. This study failed to analyse the presence of posterior vitreous detachment as a risk factor for macular holes, but investigated a number of other risk factors. Only elevated plasma fibrinogen was identified as a clearly significant risk factor. However, this may represent a chance finding only, as cautioned by the authors (Eye Disease Case-Control Study Group 1994).

Pathogenesis

Early theories of macular hole pathogenesis involved a degenerative process, possibly due to vascular insufficiency (Duke-Elder & Dobree 1967; Aaberg 1970). Gass emphasized the role of the vitreous and hypothesized that tangential traction, perhaps caused by Müller cell proliferation and subsequent contraction in the vitreoretinal interface, was the prime factor in the pathogenesis of macular holes (Gass 1988, 1995; Johnson & Gass 1988). The importance of the vitreous in the pathogenesis of macular holes is emphasized by the low frequency of macular holes in eyes with complete posterior vitreous detachment (Akiba et al. 1990a, 1990b; Kakehashi et al. 1996; Lewis et al. 1996; Ezra 2001). Also, macular holes have been shown to be less prone to enlargement, with consequent better preservation of vision, if posterior vitreous detachment is apparent at the time of diagnosis (Hikichi et al. 1993, 1995a; Hikichi & Trempe 1993).

A key element in Gass's theory is that the macular hole is not a punched out lesion with loss of foveal photoreceptors, but instead the result of a dehiscence and subsequent centrifugal displacement of photoreceptors (Gass 1995). This theory is attractive because, contrary to earlier theories that involved degeneration or loss of foveal photoreceptors, it can explain the restoration of VA to near normal levels, as often occurs after macular hole surgery. Histopathological examination of surgically removed operculae in cases of macular hole has demonstrated that, in many cases, these only contain glial elements, confirming that formation of a macular hole does not necessarily involve loss of foveal cones (Madreperla et al. 1995; Ezra et al. 1997). On the other hand, more recent histopatholog-

ical data, as well as OCT findings, indicate that in some macular holes significant amounts of foveal tissue, including cones, are torn from the foveal area (Ezra et al. 2001; Tanner et al. 2001). The most direct evidence for the lateral displacement of photoreceptors during the development of macular holes was provided by Jensen & Larsen (1998) in an elegant study using binocular kinetic perimetry. The lateral displacement of foveal photoreceptors adeptly explains the typical 'pin cushion' distortion relayed by macular hole patients (Fig. 2).

Since the advent of OCT, Gass's theory has been revised (Fig. 3). Recent studies employing OCT and ultrasound have made it apparent that in most cases of impending macular holes, there is perifoveal vitreous detachment with focal

attachment of the vitreous to the foveal umbo as well as a cystic cleavage in the inner part of the umbo (Gaudric et al. 1999; Azzolini et al. 2001; Haouchine et al. 2001; Johnson et al. 2001; Tanner et al. 2001). In the foveal umbo, the central glial element is the Müller cell cone, which, like the hub in a bicycle wheel, keeps the radially oriented neural elements centred in the foveal (Gass 1999). Anterior-posterior vitreomacular traction on the surface of the foveal umbo is thought to cause a cleavage between the Müller cell cone and the foveal photoreceptors, causing the cystic lesion seen on OCT (Gaudric et al. 1999; Azzolini et al. 2001; Haouchine et al. 2001; Johnson et al. 2001; Tanner et al. 2001). Transition from an impending hole to a stage 2 full thickness hole starts with a dehis-




Fig. 2. The typical pincushion metamorphopsia described by patients with recent onset full thickness macular holes. On the left are undistorted images. The pincushion-distorted images are shown on the right. (A) The dragging of the lines in the Amsler-grid towards the centre. (B) The typical distortion of a face, where the features are pulled inward towards the point of fixation. Pincushion distortion is caused by the centrifugal displacement of the foveal photoreceptors. After Saito et al. (2000).

cence in the roof of the cystic lesion. Centrifugal traction, the cause of which remains elusive, causes the dehiscence to spread outwards into the photoreceptor layer, causing a full thickness defect. (Gass 1999; Gaudric et al. 1999; Haouchine et al. 2001). In some cases, the dehiscence spreads around the roof of the cyst in a can-opener fashion, resulting in a small operculum that can be seen sus-

pending in front of the hole (Kim et al. 1995; Gaudric et al. 1999; Haouchine et al. 2001). Continuing centrifugal traction will, over time, cause the hole to enlarge and become more rounded (Kim et al. 1995, 1996; Hikichi et al. 1995a, 1995b; Freeman et al. 1997; Chew et al. 1999; Casuso et al. 2001).

Natural history

Impending macular holes can resolve, remain stable or progress to full thickness macular holes. If complete posterior vitreous detachment develops, the fovea can return to normal, or a lamellar hole can develop if some part of the Müller cell cone is torn off the retinal surface (Gass 1988). In the Vitrectomy for Prevention of Macular Holes Trial, 35 patients with stage 1, or impending, macular holes were followed for 24 months without intervention. In 40% of these patients, the stage 1 hole progressed to a full thickness macular hole (De Bustros 1994). Initial VA of 20/40 or better was indicative of a favourable prognosis for stage 1 macular holes in this study (Kokame & De Bustros 1995). In a retrospective study of 40 eyes with stage 1 macular holes, 48% regressed, 29% remained stable, and 23% progressed to full thickness holes within 1 year. All the stage 1 holes that regressed either had a posterior vitreous separation at baseline or developed one during follow-up. (Hikichi et al. 1995b). In a smaller series of 23 stage 1 macular holes, spontaneous resolution was noted in 22% of cases (Kakehashi et al. 1995).

Stage 2 macular holes can remain stable, close spontaneously, or enlarge (Johnson & Gass 1988; Hikichi et al. 1995a, 1995b; Kim et al. 1996; Casuso et al. 2001). In the Vitrectomy for Macular Hole Trial, 19 eyes with stage 2 macular holes were followed for 1 year. During this time, three holes (16%) spontaneously closed, two holes (10%) remained stage 2, and the remaining 14 (74%) progressed to stage 3 (Kim et al. 1995). In this study, closure of the macular hole was defined as complete flattening of the edges of the hole, and not a return to a normal foveal appearance (Kim et al. 1995). In a series of 17 stage 2 macular holes, spontaneous closure and concomitant increase in VA was reported in three (18%) eyes. However, in only one of these eyes did the foveal contour return to normal; in the two other eyes, the break remained, but with flattened edges

(Kakehashi et al. 1995). In a retrospective series of 48 eyes with stage 2 macular holes and 2 years' follow-up, the hole enlarged in 85% of these eyes and remained stable in the other 15%. No spontaneous closure was reported (Hikichi et al. 1995a). Another study found all of 15 eyes with stage 2 macular holes progressed to stages 3 and 4 after 5 years of follow-up (Casuso et al. 2001). Enlargement of the macular hole is associated with loss of vision and poorer prognosis for macular hole surgery (Hikichi et al. 1995a; Ullrich et al. 2002).

Stage 3 and stage 4 macular holes rarely close spontaneously. In the Vitrectomy for Macular Hole Trial, spontaneous closure was found during the 6 months follow-up in 4% of 65 eyes randomized to observation. Again, in this study, closure was defined merely as a flattening of the edges of the hole, and not as a return to normal foveal morphology (Freeman et al. 1997). In the Eye Disease Case-Control Study, 122 eyes with full thickness macular holes were followed for at least 1 year. Three of these eyes (2.5%) showed 'spontaneous regression or complete resolution'. However, the stage of these macular holes at baseline was not reported (Chew et al. 1999). The study also reported 48 eyes with stage 3 and stage 4 macular holes followed for more than 5 years. In these eyes, the macular holes either remained stable or enlarged, and VA slowly declined to the 20/200–20/400 level (Casuso et al. 2001).

A macular hole only rarely causes a rhegmatogenous retinal detachment (Aa-berg 1970). Only highly myopic eyes with a posterior staphyloma seem to be at risk (Akiba et al. 1999).

Risk for fellow eyes

For a patient with a newly diagnosed full thickness macular hole, an important consideration in deciding whether or not to proceed with surgery concerns the risk of developing a macular hole in the fellow eye. There are two important factors to consider when determining this risk (Ezra 2001). The first concerns the presence of a stage 1 macular hole in the fellow eye, which implies a high risk (40%) of full thickness macular hole formation in this eye within 1 year (Kim et al. 1995; Ezra 2001). The second concerns the state of the posterior vitreous. If the posterior vitreous is detached in the fellow

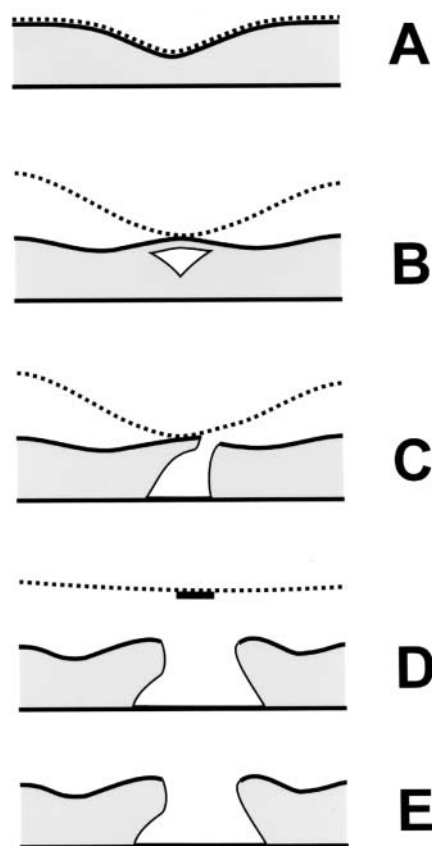


Fig. 3. A diagrammatic representation of macular hole pathogenesis, as evidenced by OCT. (A) Diagram of a normal fovea. The attached posterior hyaloid is indicated by a dotted line. (B) An impending macular hole with a cystic space in the inner part of the foveal umbo. There is a perifoveal detachment of the posterior hyaloid, which exerts anterior–posterior traction on the foveal umbo. (C) Stage 2 macular hole, with a dehiscence in the roof of the foveal cyst. This dehiscence has expanded outwards and a full thickness macular hole has developed. (D) Fully developed stage 3 macular hole. The hyaloid is detached from the fovea, but not from the optic disc. A small pseudo-operculum, consisting of the roof of the foveal cyst, is suspended in front of the macular hole. (E) Stage 4 macular hole, with complete posterior vitreous detachment, usually with a visible Weiss's ring.

eye, then this eye has a very low risk (< 2%) of progression to a full thickness macular hole (Trempe et al. 1986; Lewis et al. 1996; Ezra 2001). The risk for a fellow eye with a normal macula and an attached posterior vitreous was addressed by Ezra et al. (1998) in a prospective study of 114 patients with unilateral full thickness macular holes. The risk of development of full thickness macular hole within 5 years in these fellow eyes was estimated by Kaplan-Meier analysis to be 15.6%. A similar value was found in a less rigorous, retrospective study (Lewis et al. 1996).

Vitrectomy for macular holes

Gass's hypothesis of tangential vitreomacular traction as the key factor in the pathogenesis of macular holes provided the theoretical background for the development of macular hole surgery (Gass 1988; Johnson & Gass 1988). Two surgical goals have been pursued:

- (1) prevention of progression of macular holes, and
- (2) closure of established full thickness macular holes.

According to Gass's hypothesis, vitrectomy with removal of tangential vitreomacular traction should be able to halt progression from impending to full thickness holes. This possibility was tested in a multicentre, randomized clinical trial known as the Vitrectomy for Prevention of Macular Hole Trial. This trial included 67 patients. It did not meet its recruitment goals, but it did nevertheless rule out the possibility of any substantial benefit to be gained from vitrectomy in eyes with impending macular holes (De Bustros 1994). Vitrectomy for the prevention of macular holes has subsequently been abandoned (Benson et al. 2001).

Kelly & Wendel (1991) developed macular hole surgery and showed that it was possible to close established full thickness macular holes. Closure of the hole was defined as the flattening of the edges and disappearance of the cuff of subretinal fluid around the hole. Their procedure includes a vitrectomy with a complete posterior vitreous separation, peeling of eventual epiretinal membranes in the macula, tamponade with long-acting gas, and positioning of the patient strictly face-down for the first postoperative week (Kelly & Wendel 1991; Wendel et al. 1993). In their initial report of

macular hole surgery in 52 patients, Kelly & Wendel (1991) were able to achieve visual improvement of two or more Snellen lines in 42% and closure of the macular hole in 73% of their patients. Several subsequent case series confirmed the feasibility and good anatomical and functional results of macular hole surgery, especially if the hole was stage 2 or had developed recently (i.e. within 6 months prior to surgery) (Wendel et al. 1993; Ryan & Gilbert 1994). In some patients, macular surgery results in the complete disappearance of the edges of the macular hole and a return to near normal appearance of the fovea, biomicroscopically and on OCT (Wendel et al. 1993; Mikajiri et al. 1999; Jumper et al. 2000).

The Vitrectomy for Macular Hole Study (VMHS) was a multicentre, randomized clinical trial set up to evaluate the newly developed macular hole surgery. It included 171 eyes with stage 2, 3 and 4 macular holes, and reported separately on the results of macular hole surgery in eyes with stage 2 holes (Kim et al. 1996), and in eyes with stage 3 or 4 holes (Freeman et al. 1997). The VMHS included 42 eyes with stage 2 macular holes, 17 of which were randomized to surgery while the remaining 25 were randomized to observation. After 12 months of follow-up, progression to stage 3 or 4 macular holes was found significantly more often in eyes assigned to observation (71%) than in eyes assigned to surgery (20%). The VMHS protocol did not allow for cataract extraction within the first 6 months after macular hole surgery. Cataract development is a very common complication of vitrectomy (De Bustros et al. 1988). Visual function assessment therefore included testing with the potential acuity meter (PAM test), which is less influenced by cataract development than traditional distance vision testing. Throughout the follow-up period, operated eyes had significantly better word reading and PAM test results. However, there was no significant difference in ETRDS visual acuity between the two groups either at 6 months or at 12 months (Kim et al. 1996). The other arm of the VMHS dealt with stage 3 or 4 macular holes and included 129 eyes, of which 64 were assigned to surgery and 65 to observation. Here, follow-up was only 6 months. At the end of follow-up, closure of the macular hole was found significantly more often in eyes assigned to surgery (69%) than in observed eyes (4%). Word reading and PAM test results were

significantly better in the operated group than in the observed group and ETRDS visual acuity averaged 20/115 in operated eyes versus 20/166 in observed eyes. Although this difference was statistically significant, after adjustment for baseline VA and size of the macular hole this significance was reduced to borderline ($P = 0.05$) (Freeman et al. 1997).

The VMHS is still the only randomized clinical trial to have compared macular hole surgery with observation. Since the visual results in the VMHS were modest, numerous attempts have been made to improve macular hole surgery. Adjunctive additives such as transforming growth factor beta, autologous serum and autologous platelets have been administered in order to promote wound healing in and around the hole. Randomized clinical trials have been conducted to test each of these additives. Although a significantly higher number of closed macular holes were seen in eyes treated with autologous platelets, none of the interventions had any significant beneficial effect on functional outcome (Thompson et al. 1998; Banker et al. 1999; Paques et al. 1999).

Recently, peeling of the inner limiting membrane (ILM) of the retina has been advocated as a standard stimulus for wound healing in the macula (Rice 1999; Brooks 2000; Mester & Kuhn 2000; Smiddy et al. 2001). Inner limiting membrane peeling is greatly facilitated if the membrane is stained with the dye indocyanine green (ICG) (Da Mata et al. 2001; Kwok & Lai 2002). Currently, ICG-assisted ILM peeling is the preferred practice for stage 3 and 4 macular holes in many Scandinavian vitreoretinal centres. However, the role of ILM peeling in macular hole surgery is controversial (Margherio et al. 2000a; Smiddy et al. 2001). The ICG dye can be detected in the eye for up to 6 weeks postoperatively (Weinberger et al. 2001), and there are concerns that ICG may be toxic to the retinal pigment epithelium (RPE), possibly by increasing the light sensitivity of the epithelium (Engelbrecht et al. 2002). Macular hole surgery with ILM peeling has been reported to result in a depressed focal macular electroretinogram when compared to macular hole surgery without ILM peeling (Terasaki et al. 2001). At present, it seems prudent to restrict the use of ILM peeling to stage 3 and 4 macular holes, and to reoperations of primarily failed cases.

Strict face-down positioning as pre-

scribed by Kelly & Wendel (1991) is difficult for elderly patients to accept. Good anatomic and functional results of macular hole surgery have been reported without face-down positioning, if a complete fill of the vitreous cavity with 15% C₃F₈ is obtained (Tornambe et al. 1997). Face-down positioning for only 4 days with only air as tamponade has also successfully been employed (Park et al. 1999). However, most surgeons feel that 7–14 days of face-down positioning are necessary for good and predictable results. For patients who are unable to tolerate face-down positioning, tamponade with silicone oil is an option (Goldbaum et al. 1998; Margherio et al. 2000b), but the silicone oil must be removed with a second operation and the functional results may not be as good as with gas tamponade (Karia et al. 2001; Kumar et al. 2002).

Because most phakic patients will develop a cataract within the first 1 or 2 years after macular hole (Brooks 2000; Paques et al. 2000), combined phakoemulsification and vitrectomy has been advocated (Kotecha et al. 2000; Simcock & Scalia 2000).

Although macular hole surgery appears rather simple, there seems to be a protracted learning curve. Even experienced vitreoretinal surgeons achieve better results after several years of practising this type of surgery (Margherio et al. 2000b). Regardless of technique, in most recent series of macular hole surgery, approximately 90% of macular holes are closed, and approximately half of patients achieve VA of 20/50 or better in the operated eye (Smiddy et al. 1997; Park et al. 1999; Brooks 2000; Byhr & Lindblom 2000; Kang et al. 2000; Margherio et al. 2000b; Da Mata et al. 2001; Smiddy et al. 2001). A small macular hole, good preoperative VA and recent onset of symptoms are good prognostic factors for a favourable functional result of macular hole surgery (Wendel et al. 1993; Willis & Garcia-Cosio 1996; Byhr & Lindblom 2000; Kang et al. 2000; Ullrich et al. 2002). Although the best functional results are obtained if surgery is performed within 6 months of onset of symptoms, a VA of 20/50 or better can be obtained in 25–50% of patients reporting symptoms for more than 1 year prior to surgery (Willis & Garcia-Cosio 1996; Scott et al. 2000). Even if a good level of VA is not achieved, patients report improvement in a number of daily life activities, such as recognizing faces, after macular hole surgery (Pearce et al. 1998).

The macular function is slow to recover after successful closure of a macular hole; VA continues to improve more than 1 year postoperatively (Leonard et al. 1997).

Macular hole surgery is not without complications. As previously mentioned, most phakic patients will develop a cataract within the first 1 or 2 years postoperatively (Thompson et al. 1995; Leonard et al. 1997; Brooks 2000; Paques et al. 2000). Posterior segment complications include retinal tears, retinal detachment, RPE alterations, late reopening of an initially successfully closed macular hole, choroidal neovascular membrane, cystoid macular oedema, visual field defects, paracentral scotomas, and endophthalmitis (Duker et al. 1994; Park et al. 1995; Banker et al. 1997; Pearce et al. 1998; Paques et al. 2000; Haritoglou et al. 2001). In the VMHS, posterior segment complications were found in 41% of operated eyes. Retinal pigment epithelial alterations were the most frequent type of complication and occurred in 33% of eyes. Retinal detachment was found in 11% of operated eyes (Banker et al. 1997). In more recent series, the frequency of complications has been more moderate, and retinal detachment should be expected in less than 5% of cases (Paques et al. 1999; Brooks 2000; Kang et al. 2000; Margherio et al. 2000a; Scott et al. 2000). Late reopening of initially successfully closed macular holes occurs in 5–10% of cases (Duker et al. 1994; Christinas et al. 1998; Paques et al. 2000). Postoperative visual field defects were encountered very frequently in the early days of macular hole surgery (Melberg & Thomas 1995; Pendergast & McCuen 1996; Bopp et al. 1997). This complication is probably related to infusion of dry air under high pressure during the fluid–air exchange, and it can be almost eliminated by not allowing infusion air pressures above 30 mmHg (Hirata et al. 2000; Gass et al. 2001). Small, usually asymptomatic paracentral scotomata have also been reported as a complication of macular hole surgery in which membrane peeling has been attempted (Haritoglou et al. 2001).

When is surgery indicated?

Macular hole surgery is a recent addition to the portfolio of procedures in vitreoretinal surgery. A randomized clinical trial

(the VMHS) conducted early in the development of macular hole surgery demonstrated the efficacy of this surgery in flattening stage 3 and 4 macular holes and modestly improving visual function. The VMHS also showed that macular hole surgery can halt the progression of stage 2 macular holes to later stages. Numerous improvements in macular hole surgery have subsequently been proposed, but no convincing evidence exists to support the supposition that any of these improvements will result in better visual ability. Recent case series have achieved flattening of more than 90% of recent onset macular holes. Restoration of central vision to 20/50 is possible in many cases. Best results are obtained for macular holes of recent onset where patients report good initial vision. Patients with macular holes should be informed about the possibility of macular hole surgery, and if they decide to proceed with surgery, the procedure should be performed without undue delay.

Acknowledgements

Dr R. Klein is thanked for information about the incidence of macular holes.

References

- Aaberg TM (1970): Macular holes: a review. *Surv Ophthalmol* **15**: 139–162.
- Akiba J, Konno S & Yoshida A (1999): Retinal detachment associated with a macular hole in severely myopic eyes. *Am J Ophthalmol* **128**: 654–655.
- Akiba J, Quiroz MA & Trempe CL (1990a): Role of posterior vitreous detachment in idiopathic macular holes. *Ophthalmology* **97**: 1610–1613.
- Akiba J, Yoshida A & Trempe CL (1990b): Risk of developing a macular hole. *Arch Ophthalmol* **108**: 1088–1090.
- Azzolini C, Patelli F & Brancato R (2001): Correlation between optical coherence tomography data and biomicroscopic interpretation of idiopathic macular hole. *Am J Ophthalmol* **132**: 348–355.
- Banker AS, Freeman WR, Azen SP & Lai MY (1999): A multicentred clinical study of serum as adjuvant therapy for surgical treatment of macular holes. Vitrectomy for Macular Hole Study Group. *Arch Ophthalmol* **117**: 1499–1502.
- Banker AS, Freeman WR, Kim JW, Munguia D & Azen SP (1997): Vision-threatening complications of surgery for full thickness

- macular holes. Vitrectomy for Macular Hole Study Group. *Ophthalmol* **104**: 1442–1452.
- Benson WE, Cruickshanks KC, Fong DS, Williams GA, Bloome MA, Frambach DA, Kreiger AE & Murphy RP (2001): Ophthalmic technology assessment. Surgical management of macular holes. A report by the American Academy of Ophthalmology. *Ophthalmology* **108**: 1328–1335.
- Bopp S, Lucke K & Hille U (1997): Peripheral visual field loss after vitreous surgery for macular holes. *Graefes Arch Clin Exp Ophthalmol* **235**: 362–371.
- Brooks HL Jr (2000): Macular hole surgery with and without internal limiting membrane peeling. *Ophthalmology* **107**: 1939–1948.
- Byhr E & Lindblom B (2000): Macular hole surgery without routine membrane excision or use of adjuvants. *Acta Ophthalmol Scand* **78**: 451–455.
- Casuso LA, Scott IU, Flynn HW Jr, Gass JD, Smiddy WE, Lewis ML & Schiffman J (2001): Long-term follow-up of unoperated macular holes. *Ophthalmology* **108**: 1150–1155.
- Cheng L, Freeman WR, Ozerdem U, Song MK & Azen SP (2000): Prevalence, correlates and natural history of epiretinal membranes surrounding idiopathic macular holes. Vitrectomy for Macular Hole Study Group. *Ophthalmol* **107**: 853–859.
- Chew EY, Sperduto RD, Hiller R et al. (1999): Clinical course of macular holes: the Eye Disease Case-Control Study. *Arch Ophthalmol* **117**: 242–246.
- Christmas NJ, Smiddy WE & Flynn HW Jr (1998): Reopening of macular holes after initially successful repair. *Ophthalmology* **105**: 1835–1838.
- Da Mata AP, Burk SE, Riemann CD, Rosa RH Jr, Snyder ME, Petersen MR & Foster RE (2001): Indocyanine green-assisted peeling of the retinal internal limiting membrane during vitrectomy surgery for macular hole repair. *Ophthalmology* **108**: 1187–1192.
- De Bustros S (1994): Vitrectomy for prevention of macular holes. Results of a randomized multicentre clinical trial. Vitrectomy for Prevention of Macular Hole Study Group. *Ophthalmol* **101**: 1055–1059.
- De Bustros S, Thompson JT, Michels RG, Enger C, Rice TA & Glaser BM (1988): Nuclear sclerosis after vitrectomy for idiopathic epiretinal membranes. *Am J Ophthalmol* **105**: 160–164.
- Duke-Elder S & Dobree JH (1967): System of Ophthalmology. Vol. X. Diseases of the Retina. London: Henry Kimpton. 1–878.
- Duker JS, Wendel R, Patel AC & Puliafito CA (1994): Late re-opening of macular holes after initially successful treatment with vitreous surgery. *Ophthalmology* **101**: 1373–1378.
- Engelbrecht NE, Freeman J, Sternberg P, Aaberg TM, Aaberg TM, Martin DF & Sippy BD (2002): Retinal pigment epithelial changes after macular hole surgery with indocyanine green-assisted internal limiting membrane peeling. *Am J Ophthalmol* **133**: 89–94.
- Eye Disease Case-Control Study Group. (1994): Risk factors for idiopathic macular holes. *Am J Ophthalmol* **118**: 754–761.
- Ezra E (2001): Idiopathic full thickness macular hole: natural history and pathogenesis. *Br J Ophthalmol* **85**: 102–108.
- Ezra E, Fariss RN, Possin DE, Aylward WG, Gregor ZJ, Luthert PJ & Milam AH (2001): Immunocytochemical characterization of macular hole opercula. *Arch Ophthalmol* **119**: 223–231.
- Ezra E, Munro PM, Charteris DG, Aylward WG, Luthert PJ & Gregor ZJ (1997): Macular hole opercula. Ultrastructural features and clinicopathological correlation. *Arch Ophthalmol* **115**: 1381–1387.
- Ezra E, Wells JA, Gray RH, Kinsella FM, Orr GM, Grego J, Arden GB & Gregor ZJ (1998): Incidence of idiopathic full thickness macular holes in fellow eyes. A 5-year prospective natural history study. *Ophthalmology* **105**: 353–359.
- Freeman WR, Azen SP, Kim JW, el Haig W, Mishell DR III & Bailey I (1997): Vitrectomy for the treatment of full thickness stage 3 or 4 macular holes. Results of a multicentred randomized clinical trial. Vitrectomy for Treatment of Macular Hole Study Group. *Arch Ophthalmol* **115**: 11–21.
- Gass JD (1988): Idiopathic senile macular hole. Its early stages and pathogenesis. *Arch Ophthalmol* **106**: 629–639.
- Gass JD (1995): Reappraisal of biomicroscopic classification of stages of development of a macular hole. *Am J Ophthalmol* **119**: 752–759.
- Gass JD (1999): Muller cell cone, an overlooked part of the anatomy of the fovea centralis: hypotheses concerning its role in the pathogenesis of macular hole and foveomacular retinoschisis. *Arch Ophthalmol* **117**: 821–823.
- Gass CA, Haritoglou C, Messmer EM, Schaumberger M & Kampik A (2001): Peripheral visual field defects after macular hole surgery: a complication with decreasing incidence. *Br J Ophthalmol* **85**: 549–551.
- Gass JD & Joondeph BC (1990): Observations concerning patients with suspected impending macular holes. *Am J Ophthalmol* **109**: 638–646.
- Gaudric A, Haouchine B, Massin P, Paques M, Blain P & Erginay A (1999): Macular hole formation: new data provided by optical coherence tomography. *Arch Ophthalmol* **117**: 744–751.
- Goldbaum MH, McCuen BW, Hanneken AM, Burgess SK & Chen HH (1998): Silicone oil tamponade to seal macular holes without position restrictions. *Ophthalmology* **105**: 2140–2147.
- Haller JA (1999): Clinical characteristics and epidemiology of macular holes. In: Madreperla SA & McCuen BW (eds). *Macular Hole. Pathogenesis, Diagnosis and Treatment*. Boston: Butterworth Heinemann. 25–36.
- Haouchine B, Massin P & Gaudric A (2001): Foveal pseudocyst as the first step in macular hole formation: a prospective study by optical coherence tomography. *Ophthalmology* **108**: 15–22.
- Haritoglou C, Ehrh O, Gass CA, Kristin N & Kampik A (2001): Paracentral scotomata: a new finding after vitrectomy for idiopathic macular hole. *Br J Ophthalmol* **85**: 231–233.
- Hikichi T, Akiba J & Trempe CL (1993): Effect of the vitreous on the prognosis of full thickness idiopathic macular hole. *Am J Ophthalmol* **116**: 273–278.
- Hikichi T & Trempe CL (1993): Risk of decreased visual acuity in full thickness idiopathic macular holes. *Am J Ophthalmol* **116**: 708–712.
- Hikichi T, Yoshida A, Akiba J, Konno S & Trempe CL (1995a): Prognosis of stage 2 macular holes. *Am J Ophthalmol* **119**: 571–575.
- Hikichi T, Yoshida A, Akiba J & Trempe CL (1995b): Natural outcomes of stage 1, 2, 3 and 4 idiopathic macular holes. *Br J Ophthalmol* **79**: 517–520.
- Hirata A, Yonemura N, Hasumura T, Murata Y & Negi A (2000): Effect of infusion air pressure on visual field defects after macular hole surgery. *Am J Ophthalmol* **130**: 611–616.
- Jensen OM & Larsen M (1998): Objective assessment of photoreceptor displacement and metamorphosis: a study of macular holes. *Arch Ophthalmol* **116**: 1303–1306.
- Johnson RN & Gass JD (1988): Idiopathic macular holes. Observations, stages of formation and implications for surgical intervention. *Ophthalmology* **95**: 917–924.
- Johnson MW, Van Newkirk MR & Meyer KA (2001): Perifoveal vitreous detachment is the primary pathogenic event in idiopathic macular hole formation. *Arch Ophthalmol* **119**: 215–222.
- Jumper JM, Gallemore RP, McCuen BW & Toth CA (2000): Features of macular hole closure in the early postoperative period using optical coherence tomography. *Retina* **20**: 232–237.
- Takehashi A, Schepens CL, Akiba J, Hikichi T & Trempe CL (1995): Spontaneous resolution of foveal detachments and macular breaks. *Am J Ophthalmol* **120**: 767–775.
- Takehashi A, Schepens CL & Trempe CL (1996): Vitreomacular observations. II. Data on the pathogenesis of idiopathic macular breaks. *Graefes Arch Clin Exp Ophthalmol* **234**: 425–433.
- Kang HK, Chang AA & Beaumont PE (2000): The macular hole: report of an Australian surgical series and meta-analysis of the literature. *Clin Experiment Ophthalmol* **28**: 298–308.
- Karia N, Laidlaw A, West J, Ezra E & Gregor MZ (2001): Macular hole surgery using silicone oil tamponade. *Br J Ophthalmol* **85**: 1320–1323.

- Kelly NE & Wendel RT (1991): Vitreous surgery for idiopathic macular holes. Results of a pilot study. *Arch Ophthalmol* **109**: 654–659.
- Kim JW, Freeman WR, Azen SP, el Haig W, Klein DJ & Bailey IL (1996): Prospective randomized trial of vitrectomy or observation for stage 2 macular holes. Vitrectomy for Macular Hole Study Group. *Am J Ophthalmol* **121**: 605–614.
- Kim JW, Freeman WR, el Haig W, Maguire AM, Arevalo JF & Azen SP (1995): Baseline characteristics, natural history and risk factors to progression in eyes with stage 2 macular holes. Results from a prospective randomized clinical trial. Vitrectomy for Macular Hole Study Group. *Ophthalmol* **102**: 1818–1828.
- Kishi S, Kamei Y & Shimizu K (1995): Tractional elevation of Henle's fibre layer in idiopathic macular holes. *Am J Ophthalmol* **120**: 486–496.
- Klein BR, Hiner CJ, Glaser BM, Murphy RP, Sjaarda RN & Thompson JT (1995): Fundus photographic and fluorescein angiographic characteristics of pseudoholes of the macula in eyes with epiretinal membranes. *Ophthalmology* **102**: 768–774.
- Klein R, Klein BE, Wang Q & Moss SE (1994): The epidemiology of epiretinal membranes. *Trans Am Ophthalmol Soc* **92**: 403–425.
- Kokame GT & De Bustros S (1995): Visual acuity as a prognostic indicator in stage I macular holes. Vitrectomy for Prevention of Macular Hole Study Group. *Am J Ophthalmol* **120**: 112–114.
- Kotecha AV, Sinclair SH, Gupta AK & Tipperman R (2000): Pars plana vitrectomy for macular holes combined with cataract extraction and lens implantation. *Ophthalmic Surg Lasers* **31**: 387–393.
- Kumar V, Banerjee S, Loo AV, Callear AB & Benson MT (2002): Macular hole surgery with silicone oil. *Eye* **16**: 121–125.
- Kwok AK & Lai TY (2002): ILM peeling in macular hole surgery. *Ophthalmology* **109**: 822–823.
- Leonard RE, Smiddy WE, Flynn HW Jr & Feuer W (1997): Long-term visual outcomes in patients with successful macular hole surgery. *Ophthalmology* **104**: 1648–1652.
- Lewis ML, Cohen SM, Smiddy WE & Gass JD (1996): Bilaterality of idiopathic macular holes. *Graefes Arch Clin Exp Ophthalmol* **234**: 241–245.
- Madreperla SA, McCuen BW, Hickingbotham D & Green WR (1995): Clinicopathologic correlation of surgically removed macular hole opercula. *Am J Ophthalmol* **120**: 197–207.
- Margherio RR, Margherio AR, Williams GA, Chow DR & Banach MJ (2000a): Effect of perifoveal tissue dissection in the management of acute idiopathic full thickness macular holes. *Arch Ophthalmol* **118**: 495–498.
- Martinez J, Smiddy WE, Kim J & Gass JD (1994): Differentiating macular holes from macular pseudoholes. *Am J Ophthalmol* **117**: 762–767.
- Melberg NS & Thomas MA (1995): Visual field loss after pars plana vitrectomy with air/fluid exchange. *Am J Ophthalmol* **120**: 386–388.
- Mester V & Kuhn F (2000): Internal limiting membrane removal in the management of full thickness macular holes. *Am J Ophthalmol* **129**: 769–777.
- Mikajiri K, Okada AA, Ohji M et al. (1999): Analysis of vitrectomy for idiopathic macular hole by optical coherence tomography. *Am J Ophthalmol* **128**: 655–657.
- Mitchell P, Smith W, Chey T, Wang JJ & Chang A (1997): Prevalence and associations of epiretinal membranes. *Blue Mountains Eye Study*. *Ophthalmol* **104**: 1033–1040.
- Paques M, Chastang C, Mathis A et al. (1999): Effect of autologous platelet concentrate in surgery for idiopathic macular hole: results of a multicentre, double-masked, randomized trial. *Platelets in Macular Hole Surgery Group*. *Ophthalmol* **106**: 932–938.
- Paques M, Massin P, Blain P, Duquesnoy AS & Gaudric A (2000): Long-term incidence of reopening of macular holes. *Ophthalmology* **107**: 760–765.
- Park DW, Sipperley JO, Sneed SR, Dugel PU & Jacobsen J (1999): Macular hole surgery with internal limiting membrane peeling and intravitreal air. *Ophthalmology* **106**: 1392–1397.
- Park SS, Marcus DM, Duker JS, Pesavento RD, Topping TM, Frederick AR Jr & D'Amico DJ (1995): Posterior segment complications after vitrectomy for macular hole. *Ophthalmology* **102**: 775–781.
- Pearce IA, Branley M, Groenewald C, McGalliard J & Wong D (1998): Visual function and patient satisfaction after macular hole surgery. *Eye* **12**: 651–658.
- Pendergast SD & McCuen BW (1996): Visual field loss after macular hole surgery. *Ophthalmology* **103**: 1069–1077.
- Rahmani B, Tielsch JM, Katz J, Gottsch J, Quigley H, Javitt J & Sommer A (1996): The cause-specific prevalence of visual impairment in an urban population. *Baltimore Eye Survey*. *Ophthalmol* **103**: 1721–1726.
- Rice TA (1999): Internal limiting membrane removal in surgery for full thickness macular holes. In: Madreperla SA & McCuen BW (eds). *Macular Hole. Pathogenesis, Diagnosis and Treatment*. Boston: Butterworth Heinemann. 125–146.
- Ryan EH Jr & Gilbert HD (1994): Results of surgical treatment of recent onset, full thickness idiopathic macular holes. *Arch Ophthalmol* **112**: 1545–1553.
- Saito Y, Hirata Y, Hayashi A, Fujikado T, Ohji M & Tano Y (2000): The visual performance and metamorphopsia of patients with macular holes. *Arch Ophthalmol* **118**: 41–46.
- Scott RA, Ezra E, West JF & Gregor ZJ (2000): Visual and anatomical results of surgery for longstanding macular holes. *Br J Ophthalmol* **84**: 150–153.
- Simcock PR & Scialia S (2000): Phako-vitrectomy for full thickness macular holes. *Acta Ophthalmol Scand* **78**: 684–686.
- Smiddy WE, Feuer W & Cordahi G (2001): Internal limiting membrane peeling in macular hole surgery. *Ophthalmology* **108**: 1471–1476.
- Smiddy WE, Pimentel S & Williams GA (1997): Macular hole surgery without using adjunctive additives. *Ophthalmic Surg Lasers* **28**: 713–717.
- Takahashi H & Kishi S (2000): Tomographic features of a lamellar macular hole formation and a lamellar hole that progressed to a full thickness macular hole. *Am J Ophthalmol* **130**: 677–679.
- Tanner V, Chauhan DS, Jackson TL & Williamson TH (2001): Optical coherence tomography of the vitreoretinal interface in macular hole formation. *Br J Ophthalmol* **85**: 1092–1097.
- Tanner V & Williamson TH (2000): Watzke–Allen slit beam test in macular holes confirmed by optical coherence tomography. *Arch Ophthalmol* **118**: 1059–1063.
- Terasaki H, Miyake Y, Nomura R, Piao CH, Hori K, Niwa T & Kondo M (2001): Focal macular ERGs in eyes after removal of macular ILM during macular hole surgery. *Invest Ophthalmol Vis Sci* **42**: 229–234.
- Thompson JT, Glaser BM, Sjaarda RN & Murphy RP (1995): Progression of nuclear sclerosis and long-term visual results of vitrectomy with transforming growth factor beta-2 for macular holes. *Am J Ophthalmol* **119**: 48–54.
- Thompson JT, Hiner CJ, Glaser BM, Gordon AJ, Murphy RP & Sjaarda RN (1994): Fluorescein angiographic characteristics of macular holes before and after vitrectomy with transforming growth factor beta-2. *Am J Ophthalmol* **117**: 291–301.
- Thompson JT, Smiddy WE, Williams GA, Sjaarda RN, Flynn HW Jr, Margherio RR & Abrams GW (1998): Comparison of recombinant transforming growth factor beta-2 and placebo as an adjunctive agent for macular hole surgery. *Ophthalmology* **105**: 700–706.
- Tornambe PE, Poliner LS & Grote K (1997): Macular hole surgery without face-down positioning. A pilot study. *Retina* **17**: 179–185.
- Trempe CL, Weiter JJ & Furukawa H (1986): Fellow eyes in cases of macular hole. *Biomicroscopic study of the vitreous*. *Arch Ophthalmol* **104**: 93–95.
- Ullrich S, Haritoglou C, Gass C, Schaumberger M, Ulbig MW & Kampik A (2002): Macular hole size as a prognostic factor in macular hole surgery. *Br J Ophthalmol* **86**: 390–393.
- Weinberger AW, Kirchhof B, Mazinani BE & Schrage NF (2001): Persistent indocyanine green (ICG) fluorescence 6 weeks after intravitreal ICG administration for macular hole surgery. *Graefes Arch Clin Exp Ophthalmol* **239**: 388–390.

Wendel RT, Patel AC, Kelly NE, Salzano TC, Wells JW & Novack GD (1993): Vitreous surgery for macular holes. *Ophthalmology* **100**: 1671–1676.

Willis AW & Garcia-Cosio JF (1996): Macular hole surgery. Comparison of longstanding versus recent macular holes. *Ophthalmology* **103**: 1811–1814.

Received on July 30th, 2002.
Accepted on August 18th, 2002.

Correspondence:

Dr Morten la Cour
Eye Department
Rigshospitalet
Blegdamsvej 9
DK 2100 Copenhagen Ø
Denmark
Tel: +45 35 45 31 77
Fax: +45 35 45 22 90
Email: m.la.cour@dadlnet.dk